



Longitudinal Overgrowth of the Forearm After Fracture Fixation with Flexible Intramedullary Nail: A Case Report and Review of the Literature

Alireza Rouhani¹, Ali Tabrizi^{2, *}, Ahmadreza Afshar² and Asghar Elmi¹

¹Department of Orthopedics, Shohada Hospital, Tabriz University of Medical Sciences, Tabriz, Iran

²Department of Orthopedics, Imam Khomeini Hospital, Urmia University of Medical Sciences, Urmia, Iran

*Corresponding author: Department of Orthopedics, Imam Khomeini Educational Hospital, Urmia University of Medical Sciences, Moderres Ave, Urmia, Iran. Tel: +98-9143130829, E-mail: ali.tab.ms@gmail.com

Received 2017 March 07; Revised 2018 January 11; Accepted 2018 January 27.

Abstract

Introduction: Pediatric forearm fracture is one of the most common upper extremity fractures in youngsters. The treatment is often non-surgical. In patients, who need surgical intervention, intramedullary nails are used. Growth disturbances in long bones of the lower extremity occur in youngsters however. Longitudinal overgrowth is very rare in the upper extremity.

Case Presentation: This report presents a five-year-old child, who had radius and ulna shaft fracture in the distal one third of his forearm. This child was treated with radius fracture fixation by flexible intramedullary nails. After six months, the child had wrist pain and limitation in range of motion. On the radiography, 4 mm increase in radius was observed.

Conclusions: Overgrowth of long bones after application of intramedullary nails is known in the lower extremity however it is uncommon in the upper extremity and the exact mechanism of this phenomenon has not yet been determined and needs further investigation.

Keywords: Pediatric Forearm Fracture, Bone Overgrowth, Intramedullary Nail

1. Introduction

Pediatric forearm fracture is one of the most common trauma injuries of the upper extremity. Most of these fractures are treated with closed reduction and immobilization by a cast (1). In cases with open injuries, both bone fractures with sever displacement and instability, often surgery interventions and alignments are appropriate. Conventional fixation methods are used for pediatric forearm fractures intramedullary nails, which include titanium elastic nail (TENS) or Krichner wires (K-wires) (2). This fixation method is widely applied in patients, who are skeletally immature. Implants can be removed after six months to one year (2). One of the complications of pediatric fractures in long bones of lower extremity is growth disturbance. Growth disturbance can occur in forms of growth arrest or overgrowth (3). Overgrowth and angular deformities after placement of TENS occur in the pediatric femur shaft fractures and some studies have addressed them (4). However, it is rare in pediatric forearm

fractures and there are only a few studies in this field. In this report, the researcher presented a child with fracture in both radius and ulna bones, who was treated with intramedullary nails.

2. Case Presentation

The patient was a five-year-old boy with radius and ulna shaft fracture in his right forearm happening as a result of falling from a bike. A pin point wound was observable in the volar surface. The radiography showed ulna and radius shaft fracture in the distal one-third ulna and radius fractures were transverse (Figure 1). Regarding the wound in volar surface of forearm and instability of fracture, the patient was recognized as a surgery candidate. He was generally anesthetized and placed in the supine position. Closed reduction was performed on the radiolucent hand table. For maintaining the reduction, a 2-mm-diameter elastic intramedullary nail was applied. Nail insertion was done by a small cut in the radial side beside the styloid of radius

by protecting the surfiacial nerve. A small proximal was embedded to growth plane for protection against the damage and the intramedullary nail was placed under fluoroscopy guide to stabilize the radius fracture. Regarding the stability of ulna, it was not stabilized. Volar wound wash and debridement were done and the cut site was repaired. Long forearm cast with 90-degree elbow flexion and neutral position of wrist were used. The cast was opened after two weeks and the stitches were removed and a shorted cast was used for four weeks. After six weeks, complete union was obtained. In follow-ups, after six months, the patient had wrist mild pain and supination and pronation motion range limitation. Control radiography showed increase of radius length relative to ulna and radial bowing was diminished (Figure 2).

Implant was removed and control radiography (after nine months) showed increase of radius growth relative to the opposite side; further measurements showed a 4-mm longitudinal increase in the radius (Figure 3). No further therapeutic interventions were used for the patient and it was decided to track it.

3. Discussion

In contrast to adult forearm fracture, pediatric forearm fracture can be treated without surgery (5). Final clinical results were satisfying and forearm function can be completely restored. The reason is the presence of tough periosteum, physis openness, and fast remodeling capacity in children. Application of intramedullary nails for fracture stabilizing in long pediatric bones is highly popular (5). Application of screw and plate is not popular in children due to side effects, such as re-fracture, failure of hardware, nerve palsy, and infection (6). One of the main advantages of intramedullary nails in children is no risk of periprosthetic fracture and less invasiveness (6). From a cosmetic point of view, it is better and it can be removed faster. Also, it has its own disadvantages, such as pin tract infection, osteomyelitis, synostosis, loss of reduction, hardware migration, hardware irritation, nerve palsy, and delay in union (5, 6).

One of the complications in treatment with intramedullary nails is the growth disturbance in the stabilized bone (4). In a study by Dai et al. on pediatric femur shaft fractures stabilized by titanium elastic intramedullary nails, overgrowth of the limb was addressed. According to their findings, Nail Canal Diameter (NCD) and fracture types were among important factors in limb

overgrowth (4). The age of the patients (two to ten years old) was another important factor mentioned in the studies (7). The exact mechanism of overgrowth has not yet been determined. However, the power of remodeling deformities angular and rotational is high in children (3). One of the reasons regarding this phenomenon is that severe trauma causes damage to blood supply to the growth plane, which can disturb growth (7). Contrary to lower extremity long bone fractures, a few studies have addressed pediatric forearm fractures, and the current knowledge is very low in this regard. This issue was addressed in a study by de Pablos et al. in 1994 on radius growth pattern after pediatric forearm fractures with conservative treatments (8). Radial overgrowth was observed in 21% of patients and radial shortening occurred in 25% of patients (8). It seems that factors effective on increase of vascularity of growth planes in femur and tibia should be investigated in pediatric forearm fractures (8).

Increase of radius growth and its deformity after fracture stabilization in children was first expressed by Williams and Szabo (9). Growth increase and angular deformity after forearm stabilization resulted in pain in the child's wrists and palmar instability (9). In a study by Yu et al. in China (10), increase of growth after pediatric single-bone forearm fracture was investigated (10). They investigated 179 patients, (five to eight years old), among which four patients had 2 to 4 mm length increase in radius. According to the results of this study, such growth increase did not need intervention and proposed hard observation in children (10). Another cause of overgrowth is ulnar growth arrest due to distal ulnar physeal (11). However, in the case there was no evidence of ulnar physeal injury.

Overgrowth of long bones after application of intramedullary nails has been proven in the lower extremity; yet, rarely happens in upper extremity and its exact mechanism is still unknown. As the site of intramedullary nail insertion is near the distal growth plane, increase of blood supply in this area can be a factor for the growth increase, however it needs further studies.

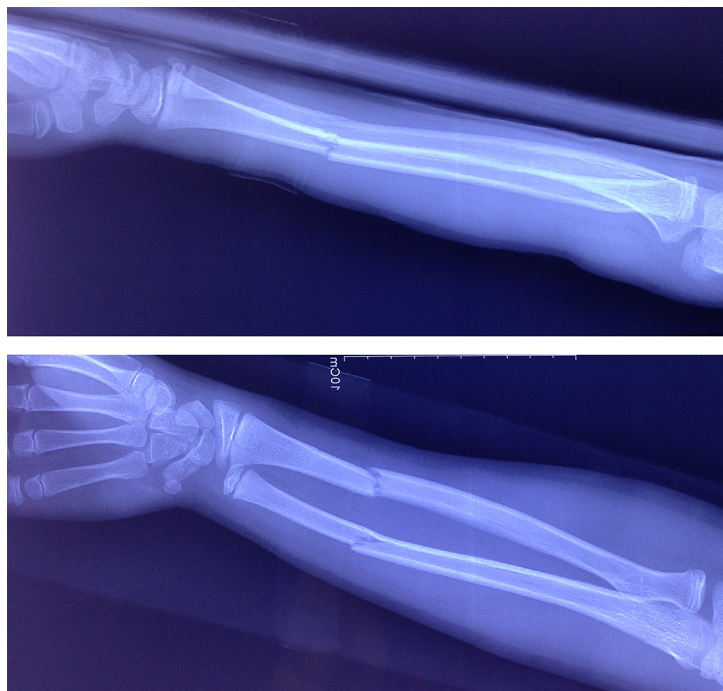


Figure 1. Standard X-ray showing a fracture of radius and ulna in the distal third of the five-year-old child.

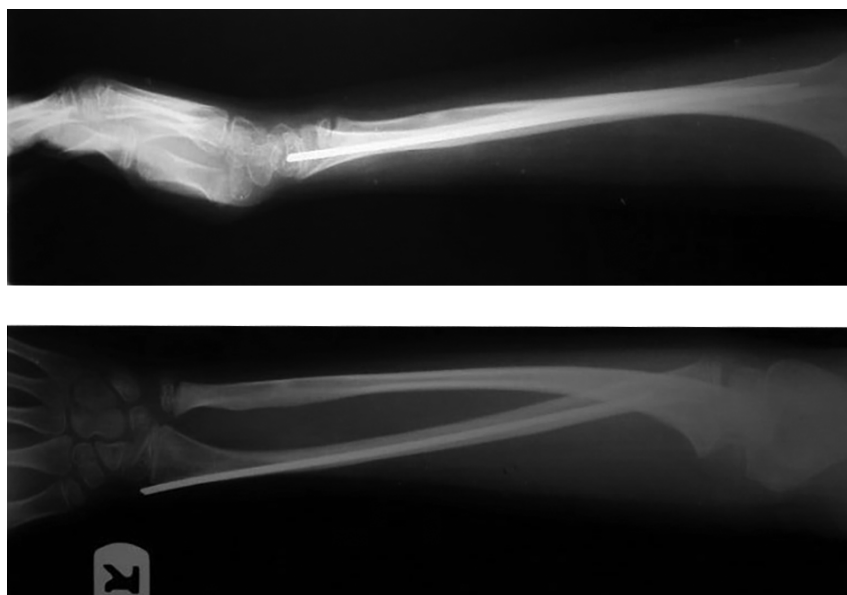

Figure 2. X-ray six months after fracture fixation represents the union in fracture site and longitudinal bone growth in the radius bone.

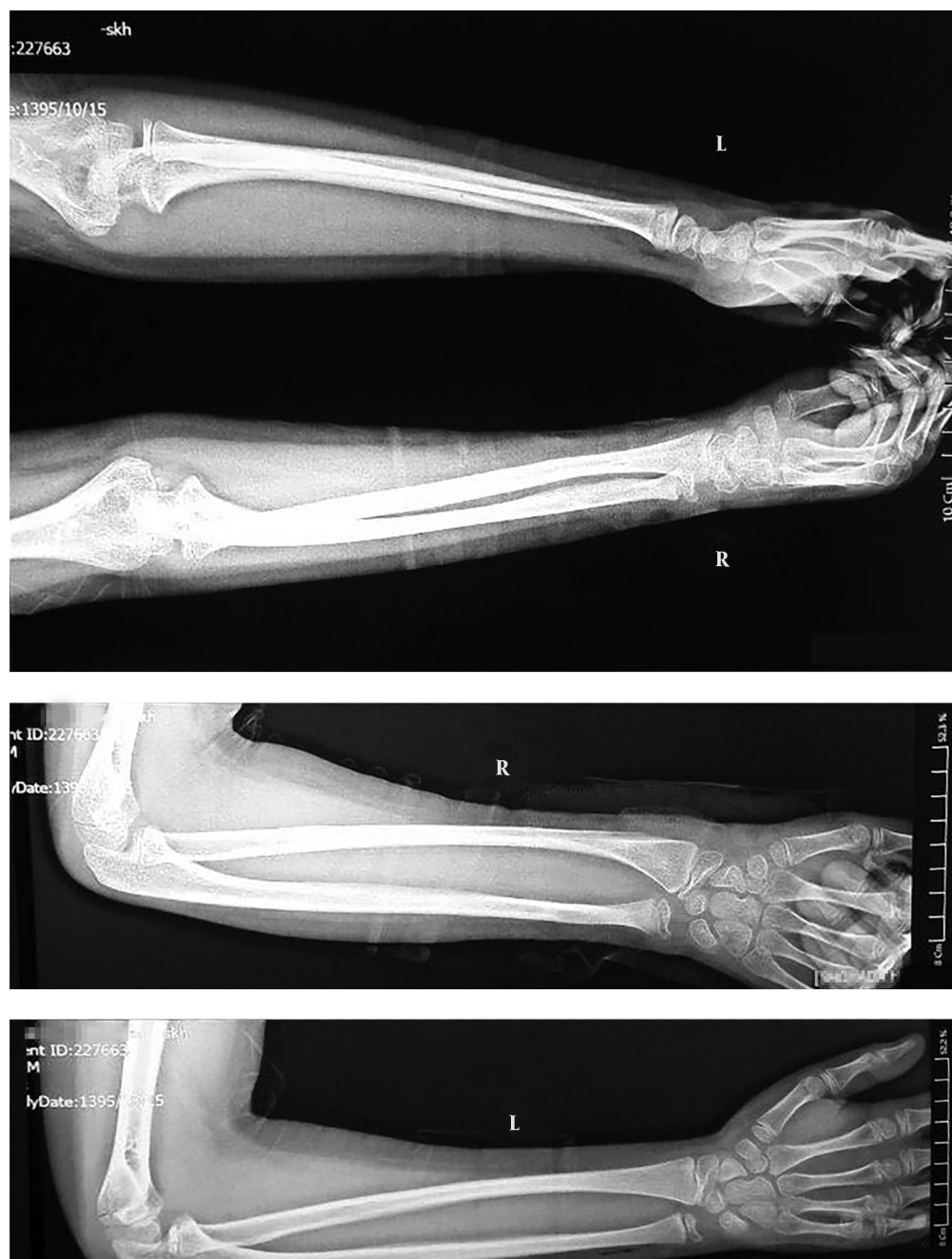

Figure 3. Comparison of two sides of the forearm with each other after the removal of intramedullary nail; represents an increase of longitudinal growth of the radial fixation with intramedullary nail and loss of longitudinal arch of radius.

References

1. Guitton TG, Van Dijk NC, Raaymakers EL, Ring D. Isolated diaphyseal fractures of the radius in skeletally immature patients. *Hand (N Y)*. 2010;**5**(3):251-5. doi: [10.1007/s11552-009-9238-z](https://doi.org/10.1007/s11552-009-9238-z). [PubMed: [19859772](https://pubmed.ncbi.nlm.nih.gov/19859772/)]. [PubMed Central: [PMC2920389](https://pubmed.ncbi.nlm.nih.gov/PMC2920389/)].
2. Kelly BA, Shore BJ, Bae DS, Hedequist DJ, Glotzbecker MP. Pediatric forearm fractures with in situ intramedullary implants. *J Child Orthop*. 2016;**10**(4):321-7. doi: [10.1007/s11832-016-0746-4](https://doi.org/10.1007/s11832-016-0746-4). [PubMed: [27271047](https://pubmed.ncbi.nlm.nih.gov/27271047/)]. [PubMed Central: [PMC4940241](https://pubmed.ncbi.nlm.nih.gov/PMC4940241/)].
3. Stilli S, Magnani M, Lampasi M, Antonioli D, Bettuzzi C, Donzelli O. Remodelling and overgrowth after conservative treatment for femoral and tibial shaft fractures in children. *Chir Organi Mov*. 2008;**91**(1):13-9. doi: [10.1007/s12306-007-0003-6](https://doi.org/10.1007/s12306-007-0003-6). [PubMed: [18320368](https://pubmed.ncbi.nlm.nih.gov/18320368/)].
4. Dai CQ, Yang J, Guo XS, Sun LJ. Risk factors for limb overgrowth after the application of titanium elastic nailing in the treatment of pediatric femoral fracture. *J Orthop Sci*. 2015;**20**(5):844-8. doi: [10.1007/s00776-015-0739-z](https://doi.org/10.1007/s00776-015-0739-z). [PubMed: [26201394](https://pubmed.ncbi.nlm.nih.gov/26201394/)].
5. Teoh KH, Chee YH, Shortt N, Wilkinson G, Porter DE. An age- and sex-matched comparative study on both-bone diaphyseal paediatric forearm fracture. *J Child Orthop*. 2009;**3**(5):367-73. doi: [10.1007/s11832-009-0197-2](https://doi.org/10.1007/s11832-009-0197-2). [PubMed: [19701786](https://pubmed.ncbi.nlm.nih.gov/19701786/)]. [PubMed Central: [PMC2758177](https://pubmed.ncbi.nlm.nih.gov/PMC2758177/)].
6. Fernandez FF, Egenolf M, Carsten C, Holz F, Schneider S, Wentzensen A. Unstable diaphyseal fractures of both bones of the forearm in children: plate fixation versus intramedullary nailing. *Injury*. 2005;**36**(10):1210-6. doi: [10.1016/j.injury.2005.03.004](https://doi.org/10.1016/j.injury.2005.03.004). [PubMed: [16122742](https://pubmed.ncbi.nlm.nih.gov/16122742/)].
7. Kuo FC, Kuo SJ, Ko JY. Overgrowth of the femoral neck after hip fractures in children. *J Orthop Surg Res*. 2016;**11**(1):50. doi: [10.1186/s13018-016-0387-9](https://doi.org/10.1186/s13018-016-0387-9). [PubMed: [27117929](https://pubmed.ncbi.nlm.nih.gov/27117929/)]. [PubMed Central: [PMC4847264](https://pubmed.ncbi.nlm.nih.gov/PMC4847264/)].
8. de Pablos J, Franzreb M, Barrios C. Longitudinal growth pattern of the radius after forearm fractures conservatively treated in children. *J Pediatr Orthop*. 1994;**14**(4):492-5. [PubMed: [8077433](https://pubmed.ncbi.nlm.nih.gov/8077433/)].
9. Williams AA, Szabo RM. Case report: Radial overgrowth and deformity after metaphyseal fracture fixation in a child. *Clin Orthop Relat Res*. 2005;(435):258-62. [PubMed: [15930948](https://pubmed.ncbi.nlm.nih.gov/15930948/)].
10. Yu Z, Wang Y, Wang C. [The influence on radioulnar joints after single-bone fracture of the forearm in children]. *Zhonghua Wai Ke Za Zhi*. 1996;**34**(4):209-11. [PubMed: [9387683](https://pubmed.ncbi.nlm.nih.gov/9387683/)].
11. Fynn J, Waters P, Skaggs D. *Rockwood and Wilkins' Fractures in Children*. Philadelphia: Lippincott Williams & Wilkins; 2015.